



PATIENT

Milo Hernandez

SPECIES

Canine

BREED

Boston Terrier

SEX

Male Intact

AGE

1 year

WEIGHT

22.8lbs

INTERPRETED BY

Maggie Machen Lamy,
DVM, DACVIM
(Cardiology)

IMAGING PERFORMED BY

G. Ferrer, DVM

HOSPITAL NAME

Pulse: Pet Ultrasound
Services

REFERRING VET

Dr. Colon

INVOICE

47534

DATE

4/13/26

PRESENTING CLINICAL SIGNS

History: Grade 4/6 heart murmur. Currently on grain-free diet. Assess prior to anesthesia for neuter.
BP: 150mmHg (stressed).

RADIOGRAPHIC FINDINGS *NOTE: Images submitted for supplemental cardiac information only.

Normal cardiac silhouette. No obvious evidence of CHF.

ECHOCARDIOGRAM FINDINGS

2D, m-mode, color flow and doppler imaging is available. Normal mitral valve leaflets with no prolapse into the left atrial lumen. No mitral regurgitation is seen, with a normal left atrial dimension. Normal LV diameter with adequate myocardial function. The tricuspid valve appears normal with no significant tricuspid regurgitation. Normal right atrial and ventricular diameter and morphology indicating no overt evidence of pulmonary arterial hypertension. The pulmonic and aortic valves are normal in morphology and mobility. Normal pulmonic and aortic outflow velocities with laminar flow. No aortic and trace pulmonic insufficiency. No obvious congenital shunts or defects are observed. No pericardial or pleural effusion noted. No obvious cardiac masses.

CARDIAC CHART

CANINE CARDIAC PARAMETERS	MR VMAX (m/s)	TR VMAX (m/s)	LA/AO (Boon method)	LA/AO (Heart Base; Swe)	FS (%)	EF (%)	EPSS (cm)
NORMAL PARAMETER	4.5-5.5	<2.7	1.3	<1.6	28-40	40-100	<0.6
PATIENT			NM	1.3	57	88	0.2
CANINE CARDIAC PARAMETERS	HR (BPM)	AV VMAX (m/s)	PV MAX (m/s)	BODY WEIGHT (kg)	LA 2D short axis Base view (cm)	LVIDd Avg; 2D and m-mode short axis (cm)	LVIDs Avg; 2D and m-mode short axis (cm)
NORMAL PARAMETER	50-100	0.7-1.7	0.7-1.6	BELOW	BELOW	BELOW	BELOW
PATIENT	100	1.5	1.0	10.3	2.0	3.3	1.4
*Normal chamber parameters expressed as a mean value (SD)				3	1.27 (5.3)	2.46 (2.46)	1.36 (5.5)
BODY WEIGHT DEPENDENT PARAMETERS				5	1.40 (4.5)	2.74 (5.2)	1.60 (4.7)
*Note: All measurements based upon multi-modal images and methods. An average value is reported.				10	1.50 (3.8)	3.27 (3.5)	2.06 (3.1)
				15	1.83 (2.0)	3.71 (2.4)	2.43 (2.1)
				20	2.02 (1.9)	4.14 (2.2)	2.80 (2.0)
				25	2.18 (2.4)	4.48 (2.9)	3.10 (2.5)
				30	2.33 (3.3)	4.83 (3.9)	3.39 (3.4)
				35	2.48 (4.3)	5.17 (5.0)	3.69 (4.5)
				40	2.62 (5.2)	5.48 (6.1)	3.96 (5.4)
				50	2.88 (7.1)	6.07 (8.3)	4.46 (7.4)

INTERPRETATION OF THE FINDINGS & FURTHER RECOMMENDATIONS

Overtly normal cardiac structural and function is identified. No significant valve leaks are appreciated, and flow through the great vessels is normal. No obvious congenital issues are seen and in the absence of a heart murmur structural disease is highly unlikely. A cause for a murmur



PATIENT

Milo Hernandez

SPECIES

Canine

BREED

Boston Terrier

SEX

Male Intact

AGE

1 year

WEIGHT

22.8lbs

INTERPRETED BY

Maggie Machen Lamy,
DVM, DACVIM
(Cardiology)

IMAGING PERFORMED BY

G. Ferrer, DVM

HOSPITAL NAME

Pulse: Pet Ultrasound
Services

REFERRING VET

Dr. Colon

INVOICE

47534

DATE

4/13/26

is not identified here, and a physiologic origin is possible. That being said, small defects are easily missed in a congenital evaluations and a grade 4 murmur is concerning. A referral should be considered for advanced evaluation if suspicion persists and the murmur is consistently prominent.

No evidence of diet-related cardiomyopathy at this time; however, utilizing a traditional diet is the conservative recommendation.

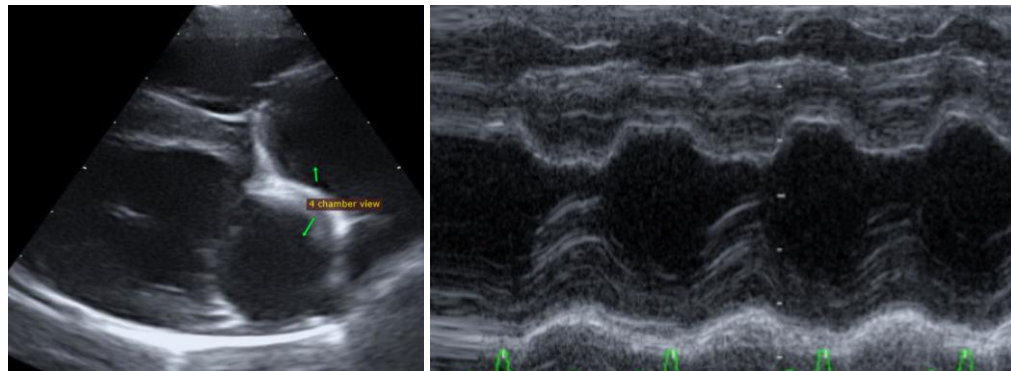
No medications are indicated at this time. Prognosis is open and there is no contraindication for general anesthesia.

Monitor for development of a heart murmur, cough, labored breathing, exercise intolerance or collapse episodes.

No contraindication for general anesthesia.

A recheck echocardiogram is recommended annually, sooner if any clinical signs arise in the interim.

IMAGES



The information and recommendations provided are based on the images presented by the referring veterinarian. No evaluation can be communicated regarding pathology that was not visible in the image/video clips provided.

Thank you for this referral. This report was generated using transcription software, and minor dictation errors may be present. If the clinical or image interpretation does not parallel your findings or if I can be of any further assistance, please contact me.

Maggie Machen Lamy, DVM
Diplomate of the American College of Veterinary Internal Medicine (Cardiology)
info@sonopath.com



PATIENT

Milo Hernandez

SPECIES

Canine

BREED

Boston Terrier

SEX

Male Intact

AGE

1 year

WEIGHT

22.8lbs

INTERPRETED BY

Maggie Machen Lamy,
DVM, DACVIM
(Cardiology)

IMAGING PERFORMED BY

G. Ferrer, DVM

HOSPITAL NAME

Pulse: Pet Ultrasound
Services

REFERRING VET

Dr. Colon

INVOICE

47534

DATE

4/13/26